

Influence of humate on calcium hydroxyapatite implants

W. Schlickewei¹, U. N. Riede², J. Yin², W. Ziehmann³, E. H. Kuner¹, and B. Seubert⁴

¹Department of Surgery (Traumatology), University Hospital, Freiburg, Germany

²Department of Pathology, University Hospital, Freiburg, Germany

³Ground Chemistry Research Group, University of Göttingen, Göttingen, Germany

⁴Weyl Chemicals, Mannheim, Germany

Summary. Implanted bovine apatite is highly osteoconductive, since it serves the host tissue as a “guide-line” for the deposition of newly developing bone tissue. It is well tolerated, but it showed no signs of being resorbed during the course of the experiment. Previous impregnation of the bovine hydroxyapatite with a low molecular humate substance obviously encourages its resorption. This is most easily explained by the known ability of humate to induce the activation of leucocytes. The occasional over-resorption of the apatite is dependent (1) upon the preparation of the implant (granulate) and (2) the local concentration of the humate. Future research is being directed towards the production of a satisfactorily usable form of humate and apatite and the investigation of its HIV blocking action on heterologous cancellous bone.

The transplantation of bone tissue is indicated in about 15% of all cases of replacement surgery of the locomotor apparatus, and it is principally employed to reconstitute actual defects in bone (see [4, 5] for literature). It is possible to repair such defects with transplants of cancellous bone from the patient or by using homologous grafts or, more recently, heterologous spongy bone from animals. Autologous transplants [1, 9] have the advantage that they initiate and promote the development of new bone, thus being “osteoinductive”. They have, however, the obvious disadvantage that only a limited amount of tissue is available. Furthermore, they require a second operation, and therefore prolong the time that the patient has to be kept on the table. Homologous transplants from a bone bank [8, 21] are scarcely available any longer in everyday clinical practice, because of the danger of transmitting the human immunodeficiency virus (HIV) and hepatitis, and because both the donor and recipient must sign a statement that they recognise the hazards. The donor has to undergo an additional test for HIV [5],

and it is also true that a reliable virostatic against HIV can only be used at the cost of accepting its toxic action on the host tissues [10, 14]. The sole heterologous bone substitutes at present available for clinical use in large quantities are the inorganic calcium compounds, in the form of hydroxyapatite or calcium triphosphate (see [7] for literature). Both of these induce the laying down of new bone, in that they act as “guide-lines” for the development of the body’s own bone tissue. They are both osteoconductive, but differ in regard to their resorbability and stability, calcium triphosphate being more quickly resorbed but less able to bear pressure, while hydroxyapatite is resorbed only to a slight degree, if at all, but is better able to withstand pressure [11, 12].

While on the lookout for a new group of active agents with the capacity to promote wound healing, we came across the humic substances. They are found naturally in peat, but they can be synthesised by the oxidation and polymerisation of the higher phenols. They are similar in structure to melanin [19, 23].

Previous experiments have established that the humic substances are able to bind to calcium-containing compounds, stimulate granulocytes to a proinflammatory reaction [13] and block the infectivity of the HIV virus in vitro [18]. In the present work we therefore decided to investigate whether coating a bovine hydroxyapatite implant with a low-molecular humic substance could induce its resorption – possibly by stimulating the leucocytes – without adversely affecting its osteoconductive properties.

Materials and methods

Humate-apatite interaction

One thousand milligrams of bovine calcium hydroxyapatite (CaHA, Bio-Oss, Geistlich, Wolhusen, Switzerland) were agitated with 10 ml of a synthetic low-molecular humate for 24 h at room temperature. A further 1000 mg bovine apatite were agitated under identical conditions with a humate (HS-1500, 0.1%; Weyl Chemicals, Mannheim) for 120 h at pH 6.1.

In both cases the mixed bone apatite-humate reaction products were washed several times in a suction filter, first with water and then with methanol. In both cases a brown reaction product was retained, from the colour of which it was clear that the humate had bonded to bone apatite. The infrared spectrum of the remaining solid bodies (possibly the reaction product) was examined. The residue was then dissolved in 0.1% nitric acid and the ultraviolet spectrum of the solution examined. Finally, the ash residue of the reaction product was analysed.

Animal experiments

Six crossbred rabbits were used. The implant material consisted of bovine hydroxyapatite (Bio-Oss), either in the form of particles or a block of cancellous bone. This bovine apatite material was implanted into the distal end of the femur and the head of the tibia in 5-mm drill-holes. Three rabbits received the untreated apatite (Bio-Oss), in the other three the same substance was coated with a humate, in this case the synthetic low-molecular humate [19]. The postoperative radiograph showed that the drill-hole was completely filled with the apatite. Histological examination of the tissue in the controls 4 weeks and 6 months after the operation confirmed that the artificial bone defect was sufficiently large to have prevented spontaneous bridging-over with bone taking place. The value of such drill-hole defects in rabbits has already been verified by Schenk and Willenegger [16] and Kathagen [6]. At the end of the 6 months, the tissue was stained by the McNeal tetrachrome block technique and embedded in methacrylate, using Schenk's method [15]. The undecalcified material was cut with a microsaw to prepare polished sections for light microscopy. Finally, the coated and uncoated apatite specimens used were critically point-dried and spattered with gold, before being examined in a Jeol Ism-35 CF scanning electron microscope.

Results

The infrared spectrum of the humate-apatite reaction product did not differ significantly from that of the untreated material. Only at a wave-length of 1600 cm^{-1} is it possible to observe widening of the bands in comparison with the control, which is probably due to the broad bands of the humic substance itself (Fig. 1). The humate-apatite reaction product was dissolved in 0.1 nitric acid and the ultraviolet spectrum of the brown-coloured solu-

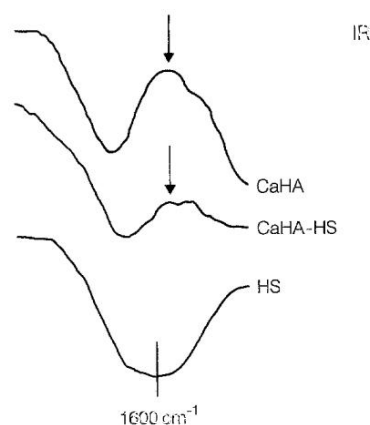


Fig. 1. Infrared spectra of the synthetic humate used (HS), the uncoated bovine calcium apatite (CaHA) and the reaction product of calcium apatite and bovine calcium apatite (CaHA-HS) at a wavelength of 1600 cm^{-1} .

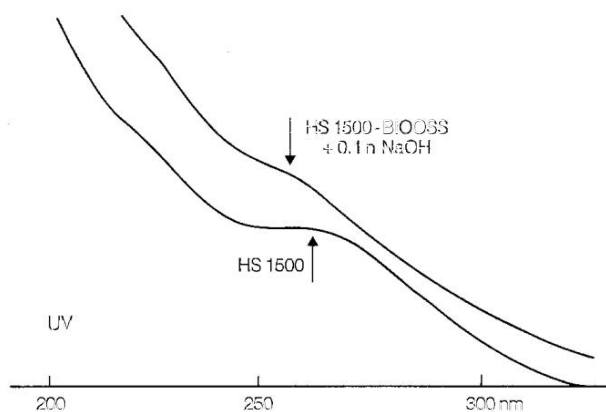


Fig. 2. Ultraviolet spectra of the synthetic humate used (HS 1500) and the reaction product of humate and bovine calcium apatite (HS 1500-Bio-OSS) at a wavelength of 200–300 nm.

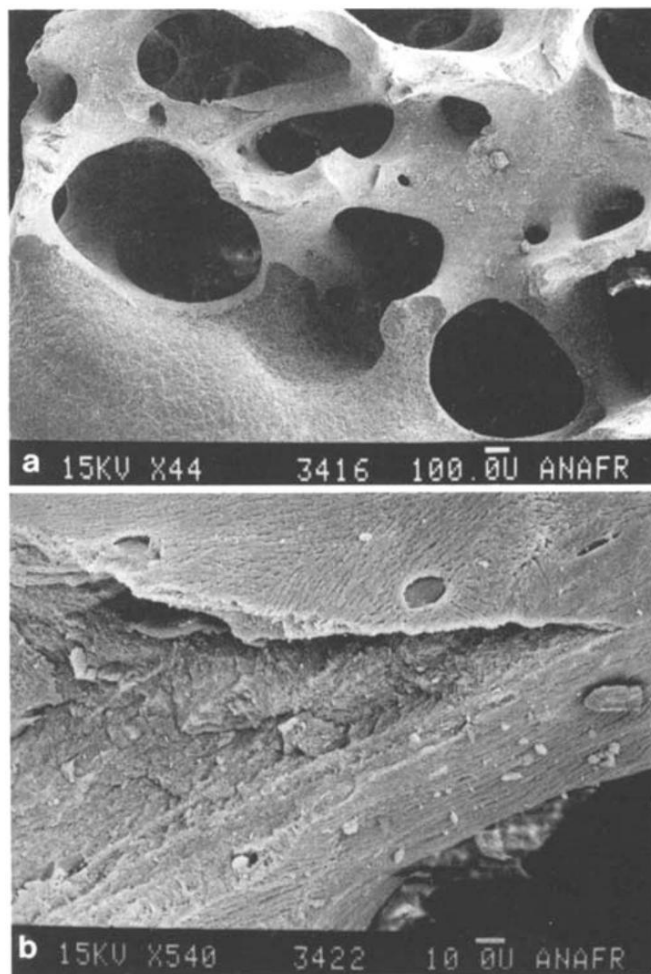


Fig. 3a, b. Scanning electron micrograph of uncoated bovine calcium apatite (Bio-Oss): a clearly recognisable remaining cancellous structure; b lamellation of the bone mineral. (Magnification: a $\times 1500$; b $\times 2500$)

tion examined (Fig. 2). This revealed that a humic substance was in fact held by the inorganic matrix, and that this showed significant changes in comparison with original humic substance. The maximum at 262 nm was absent, and a peak was only to be found at 255 nm. Analysis

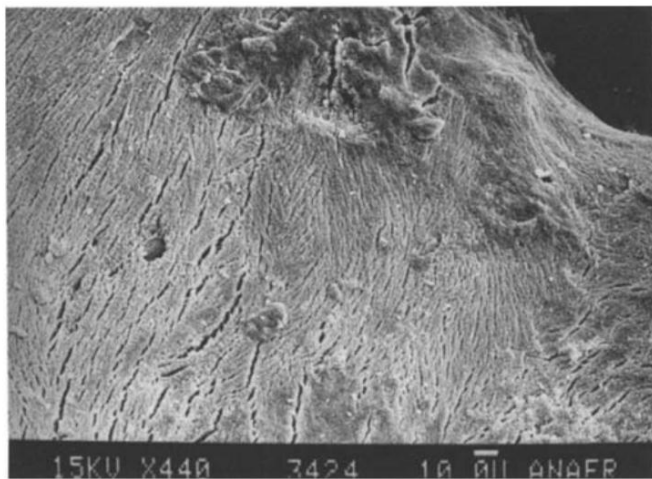


Fig. 4. The apatite crystals are orientated parallel to one another after being coated with humic substance, as they are in the uncoated apatite. (Magnification: $\times 3500$)

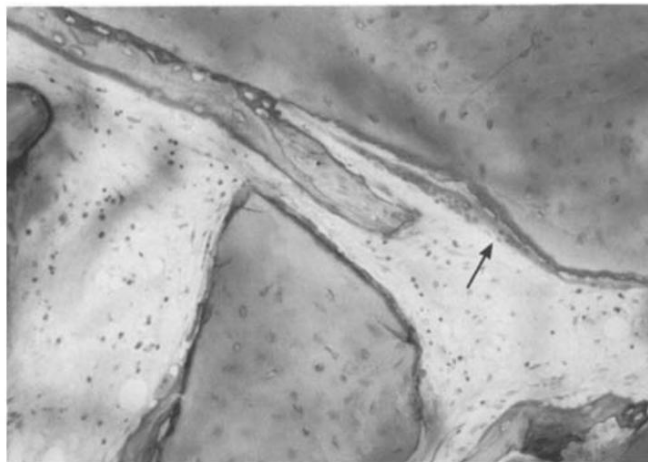


Fig. 6. The uncoated apatite is partly covered by giant osteoclasts, laid out like tiles (*arrow*). Undecalcified micro-saw section. (Magnification: $\times 150$)

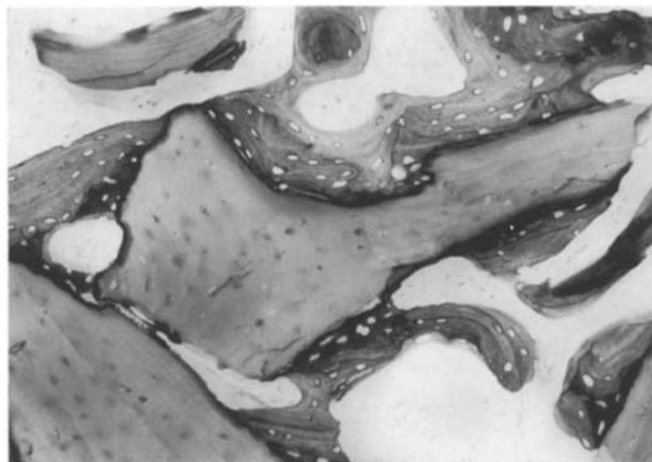


Fig. 5. In the control animals, the cancellous bovine apatite near the former drill-holes is surrounded by newly formed bone tissue. Undecalcified micro-saw section. (Magnification $\times 150$)

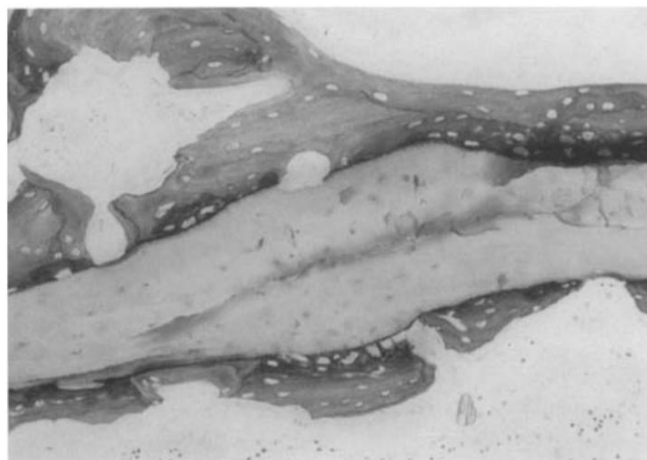

Fig. 7 The humate-coated apatite is also surrounded by newly formed bone tissue. Undecalcified micro-saw section. (Magnification: $\times 150$)

of the ash could be supposed to provide a clue to the quantity of humic substance held in the matrix.

This analysis revealed an ash content for untreated bovine apatite of 94.2%, and therefore a volatile component of 6%, whereas the humate reaction product still contained only 90.2% ash. This would mean that the content of the bovine apatite included 4% of fixed humic substances.

Scanning electron microscopic analysis of the bovine apatite revealed a cancellous structure with lamellar stratification at the edges of the specimens (Fig. 3). Higher magnification made it possible to distinguish the parallel apatite crystals surrounding the empty osteocyte lacunae. Coating with humic substance had no altered either the form or the orientation of the apatite crystals (Fig. 4).

In the neighbourhood of the former drill-hole, the devitalised apatite implant showed histological evidence of being surrounded by new lamellar bone tissue (Fig. 5).

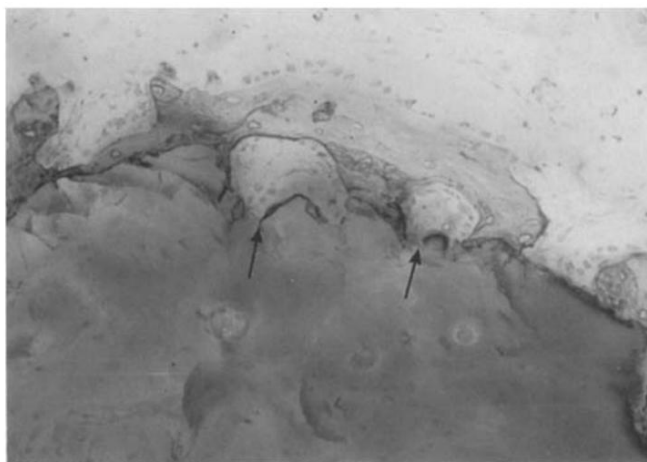


Fig. 8. Osteoclastic resorption lacunae (*arrows*) appear on the surface of the humate-coated implant; the apatite material has been eaten away, producing a crumpled appearance. Undecalcified micro-saw section. (Magnification: $\times 150$)

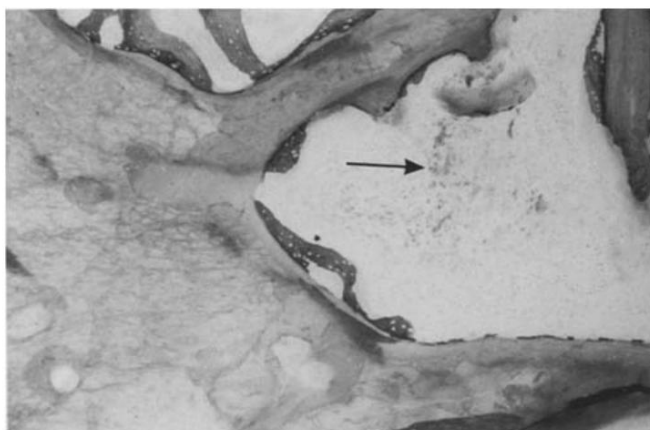


Fig. 9. Numerous histiocytes (arrow), loaded with a brownish breakdown product apparently containing humate, are located adjacent to the humate-coated implant. Undecalcified micro-saw section. (Magnification: 150 ×)

It was very noticeable that the osteoclastic resorption lacunae could be found only near the new bone, and not on the surface of the implanted devitalised bone apatite. The few but large osteoclasts were spread out on the apatite-like tiles, but without any signs of resorption lacunae (Fig. 6). A few histiocytes, some of which had stored a fine granular material, were seen between the newly formed bone trabeculae and the implanted apatite.

The humate-coated apatite implant was also surrounded by newly formed bone tissue (Fig. 7), but here osteoclastic resorption lacunae appeared at the surface of the implant also. In places the implant could be seen to have been morphologically reduced, or resorbed, so that here and there the apatite implant had the creased appearance of tissue paper (Fig. 8). This fits in with the rich assemblage between the bone trabeculae of histiocytes which had phagocytosed a brownish granular material with the typical appearance of humate (Fig. 9).

Discussion

Both under the light and the scanning electron microscope, the untreated bovine apatite revealed the characteristics of devitalised lamellar bone tissue in the region of the former drill-hole. It was surrounded by newly formed fibrous bone, which had obviously been transformed into lamellar bone tissue a few weeks after implantation by somewhat vigorous osteoclastic activity. This is remarkable in that all protein had been thoroughly removed from the apatite implant, which contained practically no organic material. It was therefore no longer capable of initiating the morphogenesis which is considered to be necessary for the formation of new bone [3]. No infiltrate of lymphocytes or granulocytes worth mentioning could be detected in the former drill-holes of the untreated control animals, so it may be assumed that the implanted bovine apatite triggered off no foreign body reaction and was therefore well tolerated by the host tissue. Furthermore, our investigation showed that the bovine apatite was largely covered by the newly formed

bone tissue, and had therefore exercised an osteoconductive action upon the reparative host tissue [17]. There was hardly any resorption during the time of the experiment, and the material was at the most subjected to physiological remodelling. This again suggests good toleration by the host tissue [20]. Furthermore, the osteoclasts had eroded no resorption lacunae in the surface of the implanted apatite particles.

If one examines those former drill-holes which had been filled with humate-impregnated apatite, enclosure of the implant by newly formed fibrous bone is already to be seen at 4 weeks, indicating that no osteoconductive action had been lost as a result of interaction with the humate. Basic new bone formation had not increased in comparison with the controls, so there is no reason to believe that there had been any humate-induced chemotactic and/or mitogenic action on the osteoblasts, which confirms similar investigations on human neutrophil granulocytes [13], endothelial cells and fibroblasts (A. Kaden, unpublished observations).

These experiments make it clear that implants of humate-impregnated hydroxyapatite develop a moth-eaten appearance, due to the vigorous action of macrophages. It is therefore not surprising to find numerous Howship's resorption lacunae between the apatite implant and the surrounding newly formed bone tissue — a sign of increasingly active remodelling and resulting in the crumpled tissue paper appearance of the apatite implant. The breakdown of the apatite is particularly associated with the implantation of cancellous granules, so that the basis for osteoconductivity is to some extent reduced. The humate-induced resorption of devitalised bone apatite may possibly be explained by the fact that low molecular humic substance has the ability to stimulate partial functioning of the leucocytes, including the macrophages, which obviously promotes the healing of skin wounds [19].

In a co-culture of keratinocytes and granulocytes, the low molecular humic substances have the capacity — rather like the tumour necrosis factor (TNF- α) — to initiate the killing of keratinocytes by stimulating leucocytes through their receptors [22]. TNF- α is a polypeptide produced by activated macrophages, and is itself a powerful granulocyte activator. Apart from that, it is also known that TNF- α promotes osteoclastic resorption and the replication of osteoblasts [2]. It is therefore conceivable that the humic substances, on account of their great capacity to bind to polyanionic bonding agents, also interact with cell receptors to liberate certain cellular factors which may, amongst other things, express themselves in the acceleration of bone remodelling. The fact that the low-molecular humate can apparently retain its osteoresorptive influence for a long time after implantation is very probably because the humic substances bind to calcium apatite, as may be proved by physical and chemical means, without themselves losing their capacity to stimulate leucocytes.

References

1. Axhausen G (1909) Die histologischen und klinischen Gesetze der freien Osteoplastik aufgrund von Tierversuchen. Arch Klin Chir 88:23–139

2. Bertolini DR, Nedwin GE, Bringman TS, Smith DD, Mundy GR (1986) Stimulation of bone resorption and inhibition of bone formation in vitro by human tumor necrosis factors. *Nature* 319:516-518
3. Canalis E, McCarthy T, Centrella M (1988) Growth factors and the regulation of bone remodelling. *J Clin Invest* 81:277-281
4. Friedländer GE (1991) Bone allografts. *J Bone Joint Surg [Am]* 73:1119-1122
5. Hackenbroch MH, Kattenhagen BD, Köhler M, Müller RT, Schlegel KF, Wirth CJ (1990) Richtlinien zum Führen einer Knochenbank. *Dtsch Arztebl* 87:41-44
6. Katthagen BD (1986) Knochenregeneration mit Knochenersatzmaterialien. *Hefte Unfallheilkd* 17
7. Kotani S, Fuyita Y, Kitsuge T, Nakamura T, Yamamuro T, Ohtsuki C, Kokubo T (1991) Bone bonding mechanism of β -tricalcium phosphate. *J Biomed Mater Res* 25:1303-1315
8. Kuner EH, Hendrich V (1984) Die allogene Knochen transplantation. *Chirurg* 55:704-709
9. Matti H (1932) Über freie Transplantation von Knochenspongiosa. *Langenbecks Arch Chir* 168:236-258
10. Merz H, Rytk G, Müller WGE, Röder W (1991) Bestimmung einer HIV-Infektion im menschlichen Knochen. *Unfallchirurg* 94:47-49
11. Osborn JF (1985) Implantatwerkstoff Hydroxylapatitkeramik. Quintessenz, Berlin
12. Pochon JP (1990) Knochenersatzplastiken mit Tricalciumphosphat im Kindesalter. *Aktuel Probl Chir Orthop*. Huber, Bern
13. Riede UN, Zeck-Kapp G, Freudenberg N, Keller HU, Seubert B (1991) Humate-induced activation of human granulocytes. *Virchows Arch [B]* 60:27-34
14. Röder W, Müller WEG, Merz H (1991) Ist Ozon zur Sterilisation HIV-infizierter Knochen geeignet? *Unfallchirurg* 94:50-51
15. Schenk RK (1965) Zur histologischen Verarbeitung von unentkalktem Knochen. *Acta Anat* 60:3
16. Schenk RK, Willenegger HR (1977) Zur Histologie der primären Knochenheilung. *Hefte Unfallheilkd* 90:155-160
17. Schliekewei W, Paul Ch (1991) Experimentelle Untersuchungen zum Knochenersatz mit bovinem Apatit. *Hefte Unfallheilkd* 216:59-69
18. Schneider J, Riede UN, Seubert B (1991) Humat-induzierte Membranfusionshemmung bei der HIV-Infektion. *Verh Dtsch Pathol Ges* 75:505
19. Seubert B, Fickert W, Spitaler U (1988) European Patent Office, Pat. Nr. 0313718-AZ
20. Spector M (1991) Charakterisierung biokeramischer Kalziumphosphatimplantate. *Hefte Unfallheilkd* 216:11-22
21. Tomford WW, Doppelt SH, Mankin HJ, Friedlaender GE (1983) Bone bank procedures. *Clin Orthop Rel Res* 174:15-21
22. Zeck-Kapp G, Nauck M, Riede UN, Block L, Freudenberg N, Seubert B (1991) Niedermolekulare Huminstoffe als proinflammatorische Zellsignale. *Verh Dtsch Pathol Ges* 75:504
23. Ziechmann W (1980) Huminstoffe. Verlag Chemie, Weinheim

Received April 23, 1993